



## PATIENT

Fergie Blackwood

## SPECIES

Canine

## BREED

Bouvier des Flandres

## SEX

FS

## AGE

10 y

## WEIGHT

36.8 kg

## INTERPRETED BY

Keith Blass, DVM, MS,  
DACVIM (Cardiology)

## IMAGING PERFORMED BY

Dr. Judy McFarlen

## HOSPITAL NAME

Westview VH

## REFERRING VET

Dr. McFarlen

## INVOICE

## DATE

3/11/26

## PRESENTING CLINICAL SIGNS

Previous echo showed mild LV systolic dysfunction. Receiving pimobendan 10 mg BID.

## ECHOCARDIOGRAPHIC FINDINGS

2D, M-mode, and Doppler study. This exam is compared to the one performed 8/6/25.

Left atrial size is normal. The mitral valve appears normal, though trace mitral regurgitation is present. The left ventricular diastolic dimension is normal. Left ventricular systolic function measures mildly below the lower limit of the normal reference interval. The aorta and aortic valve appear normal, though trace aortic insufficiency is present. Right atrial and right ventricular dimensions are normal. The tricuspid valve appears normal, though trace tricuspid regurgitation is present. The pulmonary artery and pulmonic valve are normal. No shunting lesions are visualized. No pericardial effusion or cardiac masses are seen.

ECG during echo: Sinus rhythm

LA - 40.8 mm (prev. 40.8 mm)  
LVIDd - 41.1 mm (prev. 41.2 mm)  
LVIDs - 37.1 mm (prev. 31.4 mm)  
FS - 23.1% (prev. 23.7%)  
RA - 28.3 mm (prev. 28.0 mm)  
LVOT - 1.88 m/s (prev. 1.49 m/s)  
RVOT - 0.74 m/s (prev. 0.70 m/s)

## ASSESSMENT/RECOMMENDATIONS

This examination is unchanged compared to Fergie's previous echocardiogram and demonstrates mild left ventricular systolic dysfunction in the absence of left heart chamber dilation. Given this, Fergie's current risk for the development of clinical signs of left-sided cardiac disease, such as coughing, exercise intolerance, syncope, and labored breathing, still appears to be low.

No change in therapy is recommended based on this exam.

A recheck echocardiogram is recommended in 9 months, sooner if new clinical signs compatible with cardiac dysfunction develop.



### PATIENT

Fergie Blackwood

### SPECIES

Canine

### BREED

Bouvier des Flandres

### SEX

FS

### AGE

10 y

### WEIGHT

36.8 kg

### INTERPRETED BY

Keith Blass, DVM, MS,  
DACVIM (Cardiology)

### IMAGING PERFORMED BY

Dr. Judy McFarlen

### HOSPITAL NAME

Westview VH

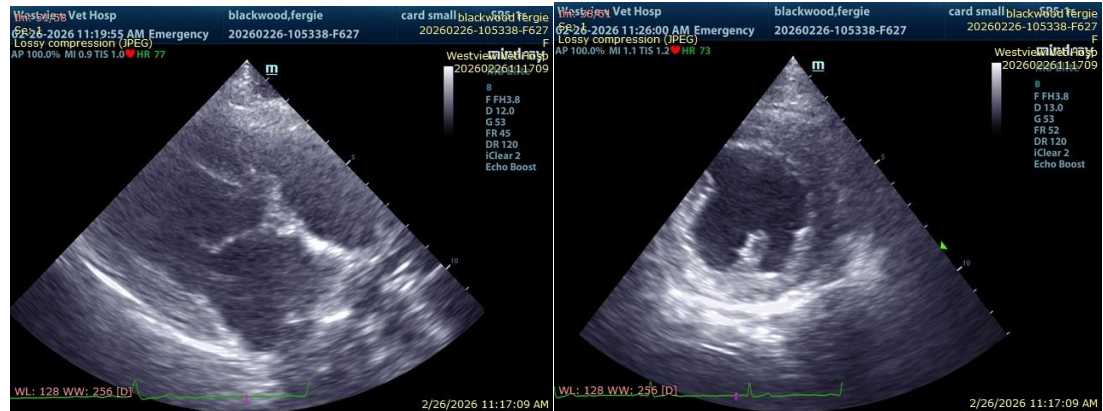
### REFERRING VET

Dr. McFarlen

### INVOICE

### DATE

3/11/26



The information and recommendations provided are based on the images presented by the referring veterinarian/sonographer. No evaluation can be communicated regarding pathology that was not visible in the image/video clips provided.

Thank you for this referral. If the clinical or image interpretation does not parallel your findings or if I can be of any further assistance please contact me.

Keith Blass, DVM, MS, DACVIM (Cardiology) [info@SonoPath.com](mailto:info@SonoPath.com)